

Medical Assisting

“P” Terms

palatine tonsil pharyngeal tonsil

palatine tonsil concerning the palate almond

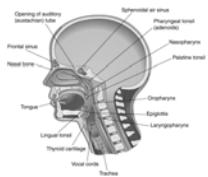- palatine tonsil lies on each side of the oral pharynx between the arches

“lymphoid tissue located on either side of the pharynx”

- pharyngeal tonsil located on the roof of the posterior wall of the pharynx

“lymphoid organs at the back of the throat”

Figure 30.5
Sagittal View of the Head and Neck



pallor

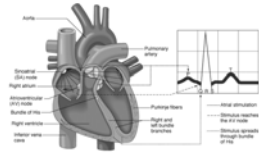
- lack of color

“pale”

palpitation

Latin to quiver

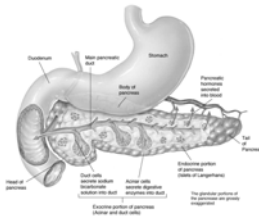
- rapid, violent, or throbbing pulsation
- an abnormally rapid throbbing or fluttering of the heart
- the palpitation is perceptible to the patient



“feeling of the heart beat within the chest”

pancreas

- glandular organ situated behind the stomach
- attached to the duodenum
- pancreatic juice aids digestion
- insulin regulates blood glucose levels

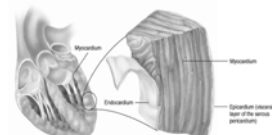


“endocrine & exocrine gland”

pericardium

peri- around
cardi/o heart
-um noun ending

- double membrane that forms the fluid filled sac around the heart

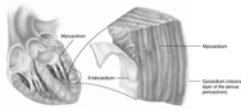


“membrane surrounding the heart”

pericarditis

peri- around
cardi/o heart
-itis inflammation of

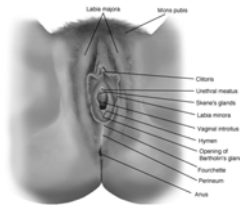
“inflammation of fluid
filled sac
surrounding the
heart”



perineum

- external region
between the vulva &
anus in a female or
scrotum & anus in a
male

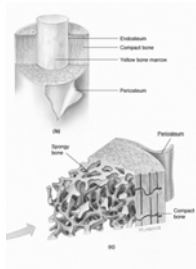
“area between the
vagina & the anus”



periosteum

- fibrous membrane covering bones
except at their articular surfaces
- external layer contains numerous
blood vessels
- inner layer of connective tissue
cells that function as osteoblasts
when the bone is injured &
participate in new bone formation
- serves as supporting structure for
blood vessels & for attachment of
muscles, tendons & ligaments

“outer covering of the
bone”

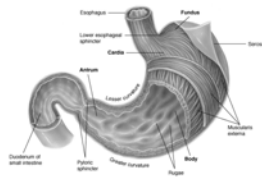


peristalsis

peri- around
stalsis contraction

- progressive, wavelike movement that occurs involuntarily

“intestinal action of contraction / relaxation

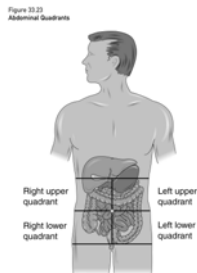


peritoneum

peri- around

- serous membrane over the viscera & lining the abdominal cavity

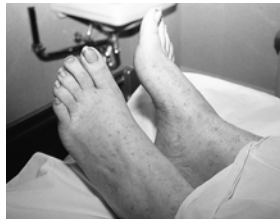“tissue lining of the abdominal cavity”



petechia

- skin spot
- small, purplish, hemorrhagic spots on the skin
- appear in certain severe fevers
- may be due to abnormality of blood-clotting mechanism

“small, round hemorrhagic spots”



phagocytosis

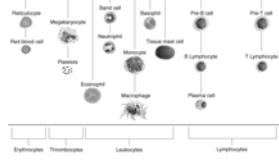
phag/o to eat, destroy

cyt/o cell

-osis condition of

- ingestion & digestion of bacteria & particles by phagocytes

“process of ingesting cells or foreign substances”

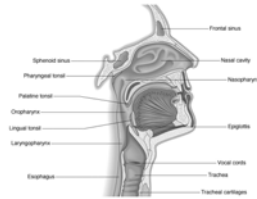

pharynx

- passageway for air from nasal cavity to larynx & food from mouth to esophagus

- communicates with the posterior nares, eustachian tube, mouth, esophagus & larynx

“the throat”

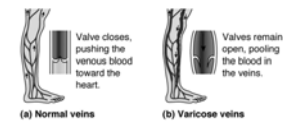


phlebitis

phleb/o vein
-itis inflammation of

- pain & tenderness along course of vein
- discoloration of skin
- inflammatory swelling & acute edema below obstruction
- may occur in acute or chronic infections or following surgery or childbirth

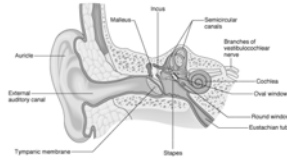
“inflammation of the vein”



pinna

Latin feather

- the auricle or projected part of the exterior ear
- collects & directs sound waves toward the tympanic membrane

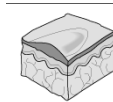


“external ear”

plaque

French a plate

- a patch on the skin or mucous surface
- a blood platelet
- yellow swollen area of the lining of an artery formed by deposition of lipid in the area
- dental plaque



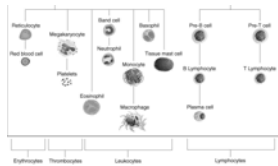
A plaque is a solid raised lesion that is greater than 0.5 cm in diameter.

“papules merged to form a lesion > 1 cm”

platelet

plate Greek, flat

- round or oval disc
- play an important role in blood coagulation, hemostasis & thrombus formation
- when vessel is injured platelets adhere to each other & cover the area

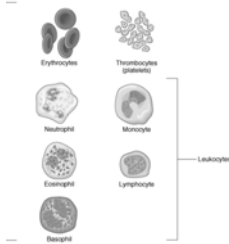


“thrombocyte necessary for coagulation”

polymorphonuclear WBC

poly- many
morph/o form

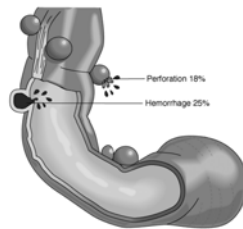
- WBC with nucleus composed of 2 or more lobes or parts
 - AKA - *granulocyte*
 - neutrophil, eosinophil, basophil
 - often referred to as "polys"
- "leukocytes with various forms of nuclei"



polyp

- Greek many footed
- a tumor with a pedicle
- commonly found in vascular organs: nose, uterus, rectum
- polyps bleed easily


"tissue mass or projection from the intestinal surface"



polyuria

poly- many
ur/o urine
-ia condition of

- excessive secretion & discharge of urine
 - UA does not, as a rule, contain abnormal constituents
 - UA virtually colorless
 - low specific gravity
 - occurs in diabetes, chronic nephritis, following edematous states, excessive fluid intake
- "increased urine production"

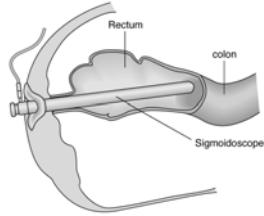


proctoscopy

procto/ anus

-scopy process of
 viewing

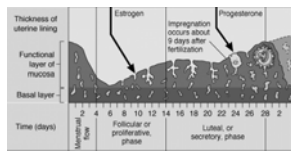
“visualization of the
rectum / anus”



progesterone

pro- before
-gestare to bear

- responsible for changes in the endometrium in the second half of the menstrual cycle
- prepares for implantation of the blastocyst, development of maternal placenta, & development of mammary glands
- used for treatment of menstrual disorders: amenorrhea, dysmenorrhea

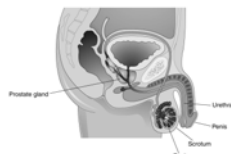


“steroid hormone secreted by
the ovary & placenta”

prostate

- gland that surrounds the neck of the bladder & urethra in the male
- partly muscular & partly glandular
- ducts open into the prostatic portion of the urethra
- secretes a thin, opalescent, slightly alkaline fluid that forms part of the seminal fluid

Figure 33.27
The Male Reproductive System



“walnut-shaped gland located
below the bladder”

prostatitis

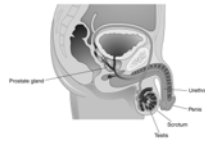
prostate
-itis inflammation of

- may be a complication of gonorrheal infection or other bacterial source

- acute or chronic

“inflammation of the prostate gland”

Figure 22.27
The Male Reproductive System

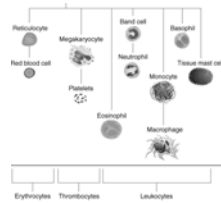


prothrombin

pro- before

thromb/o clot

“protein necessary for blood clot formation”



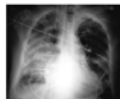pulmonology

pulmon/o lungs

-logy study of

“study of the lungs”

Figure 22.3
Posterior-Anterior Chest X-ray of a Patient with Pneumonia
The patient's right lung contains fluid due to pneumonia. This increases the attenuation of x-rays and gives the lung field a white appearance.

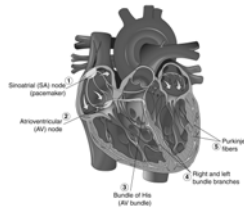


Purkinje fibers

- atypical muscle fibers lying beneath the endocardium
- they form the electrical impulse-conducting system of the heart

“specialized cells of the cardiac conduction system”

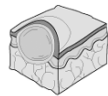
Figure 23.4
The Conduction System of the Heart



pustule

- Latin blister
- small elevation of skin filled with lymph or pus

“small, round, raised pus-filled lesion”



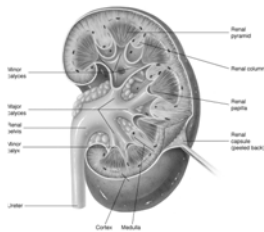
A **pustule** is a small circumscribed elevation of the skin containing pus.

pyelonephritis

- pyel/o pelvis
nephro/o kidney
-itis inflammation of

- usually due to bacteria that have ascended from the bladder after entering through the urethra
- *escherichia coli* – *E coli* is the cause in 85% of cases

“inflammation of the internal structures of the kidney”

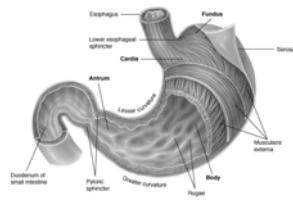


pyloric sphincter

pylor/o gatekeeper

-ic pertaining to

“muscular band between the stomach and the duodenum”



pyuria

py/o pus

ur/o urine

-ia condition of

- freshly passed urine may be cloudy due to presence of pus

“pus in the urine”

