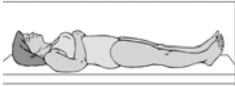


Neurological Tests


Used to diagnose common neurological disorders

Computed Tomography (C.T.)
Quickest, easiest, least expensive method of diagnosing neurologic problems.



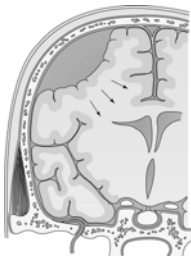- With computer, pictures taken at many horizontal levels, of brain or spinal cords.
- Contrast media may or may not be used.
- Distinguish bone, soft tissue, and fluid.
- Tumors, infarctions, hemorrhage, hydrocephalus, and bone malformations can be identified.

Client Preparation



- Nurse explains procedure, 10-40 minutes or less.
- Any allergies to contrast media, shellfish, or iodine.
- No hairpins, hairpieces/wigs
- No food for 4-6 if contrast used.
- Fluids are usually allowed.
- Consent signed.
- Sedative ordered if necessary.

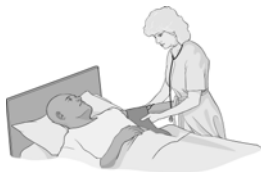Procedure



Subdural hematoma

- Head positioned in a holding device on a movable table.
- Client must remain still.
- Table moved into a large cylinder-type structure.
- Client may be fearful of confinement in a small space.
- Noncontrast series taken first.
- IV injection of contrast media enhance the vascular system.
- Open CT machine available now

Follow-Up Care



- Check for delayed allergic response to contrast media.
- Contrast media results in diuresis, observe for S/S dehydration.

Magnetic Resonance Imagery (MRI)

- Most sensitive technology for detecting abnormalities of brain and spinal cord.
- More accurate in making diagnoses.
- MRI's of spine have replaced CT scans
- Images superior to CT scan
- Does not use ionizing radiation
- Relies on magnetic fields.

Client Preparation



- Signed consent. Remove all jewelry
- No food or fluid restrictions.
- Nurse informs patient that:
 1. procedure is noisy (earplugs)
 2. will lie on hard, cold surface
 3. will be inside a hollow tube
 4. sedative administered if claustrophobic.
- MRI contraindicated in clients: who are confused, pregnant, agitated, unstable VS, continuous life support, implanted ferromagnetic devices (prostheses, clips, pacemakers) or tattoos.

Procedure - MRI

- MRI uses magnets, hydrogen nuclei (protons) and body's response to the magnetic fields to align the cells.
- Radiofrequency waves applied to aligned cells cause them to spin (resonance)
- When nuclei relax and return to original position, small radiofrequency signals are produced.
- These signals are detected and interpreted by computer and translated into cross-sectional images.
- No special postprocedure or follow-up care is required.

Lumbar Puncture-spinal tap

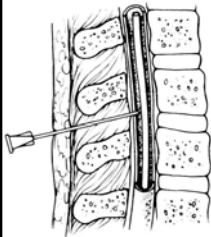
- The insertion of a spinal needle into the subarachnoid space between the third and fourth (sometimes fourth and fifth) lumbar vertebrae.
- A lumbar puncture may be done to do the following:
 - Obtain pressure readings with a manometer
 - Obtain CSF for analysis
 - Check for spinal blockage
 - Inject contrast medium or air for diagnostic study.
 - Inject spinal anesthetics or certain meds.
 - Reduce mild/mod increased intracranial pressure in certain conditions.
- Danger of sudden release of CSF pressure, contraindicated if client has symptoms of ICP.
- Sudden release of CSF pressure causes a shift of cranial tissue, resulting in more brain damage.
- Contraindicated in clients with skin infections at or near puncture site.

Client Preparation



- Informed consent.
- Nurse explains procedure
- Some discomfort felt when local anesthetic is injected.
- May experience pain in the leg
- Have client empty their bladder.
- Place patient on side of preference.
- Back close to the edge of the bed/table
- Hold pt. In fetal position behind knees and chin on chest.
- A pillow under head and between knees aids body alignment.

Procedure - lumbar puncture



- Dr. cleans insertion site with Betadine.
- Local anesthetic is injected
- Spinal needle inserted between 3rd/4th lumbar vertebrae.
- Nurse informs client to inform them if a shooting pain or tingling sensation is felt.
- Subarachnoid space determined (CSF)
- Client asked to relax for pressure reading. Opening and closing readings taken and recorded.
- 3-5 test tubes of CSF collected, numbered sequentially.
- Needle withdrawn, slight pressure applied, adhesive bandage applied.

Follow- Up Care - lumbar puncture

- Client restricted to bedrest, head flat X 4-8 hrs.
- Prevents leakage of CSF from puncture site.
- Nurse instructs client to increase fluid intake to 3000ml X 24-48 hrs.
- Decrease in CSF may cause severe, throbbing headache.
- Nurse administers analgesics prn.
- Observe level of consciousness frequently as ordered.
- Complications include infection, leakage of CSF, and hematoma formation.

Electroencephalography - EEG

- Records the electrical activity of the cerebral hemispheres.
- Graphic recording represents the voltage changes in various areas of the brain.
- EEG may be normal even when pathology is present
- The test is performed to:
 - Determine the general activity of the cerebral hemi.
 - Determine the origin of seizure activity (epilepsy)
 - Determine cerebral function in pathologic conditions.
 - Differentiate between organic and hysterical or feigned blindness or deafness.
- Monitor cerebral activity during surgical anesthesia.
- Diagnose sleep disorders (all night EEG)
- Determine brain death.

Client Preparation- EEG

- Nurse explains purpose and procedure for the test.
- If order is for the client to be “sleep deprived,” client should awaken 2-3A.M. and stay awake.
- Client to avoid CNS depressants/stimulants.
- Anticonvulsants withheld only if Dr. orders
- Client to avoid caffeine-containing fluids
- Reassure client test is not dangerous or painful.
- Client to wash hair morning of test. No hairpins, sprays, oils, ect.
- Wash hair after test to remove electrode glue.

Procedure

- Client positioned in a reclining chair or bed.
- 16-24 electrodes are attached to the scalp with jelly-like substance and connected to the machine.
- Glue is then placed over electrodes to prevent slippage.
- Client must lie still during initial recording.
- The rest of test will engage client in certain activities.
- Portable EEG may be done @ bedside pm, but preference is for it to be done in a room devoid of stimuli.
- Hyperventilation (vasoconstriction/alkalosis) ^ likelihood of seizure activity. To breathe deeply 20-30 times for 3min.
- Photic stimulation- strobe light determines if photosensitive
- Sleep(natural/induced)epilepsy best demonstrated in temporal lobe during sleep.
- Throughout test (40-60 minutes) any movement is recorded as artifacts..

Follow-Up Care

- Remove jelly-like substance and glue from scalp with acetone, then shampoo.
- Client may need a nap id sleep deprived.
